

Poland's Syndrome: Clinical Study

Riyaz Ahmed F.K.*, Sudhir D.**

Abstract

Poland syndrome is a unique rare congenital anomaly characterized by the defect of the chest (Pectoralis) muscle on one side of the body and acromelia with webbing of the fingers (cutaneous syndactyly) of the ipsilateral hand. We report a 9 year old girl with most features of Poland syndrome on right side.

Keywords: Poland's Syndrome; Acromelia; Cutaneous Syndactyly.

Case Report

A nine-year old girl presented with congenital deformity of right-sided chest and right hand. She was first child of non-consanguineous marriage with normal development till age. Her sister was normal. On examination, right sided chest muscle and nipple were absent with acromelia and cutaneous syndactyly involving middle three fingers of the same side. Scapula of same side was small. No other anomaly

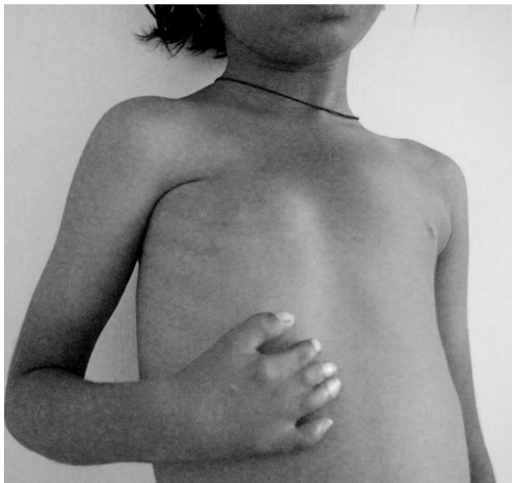

Fig. 1: Photograph showing absence of right nipple and right-sided subcutaneous tissue with right-sided acromelia with syndactyly involving middle-three fingers

was observed on gross examination. Vitals and systemic examination was normal.

Hematological and biochemical parameters were

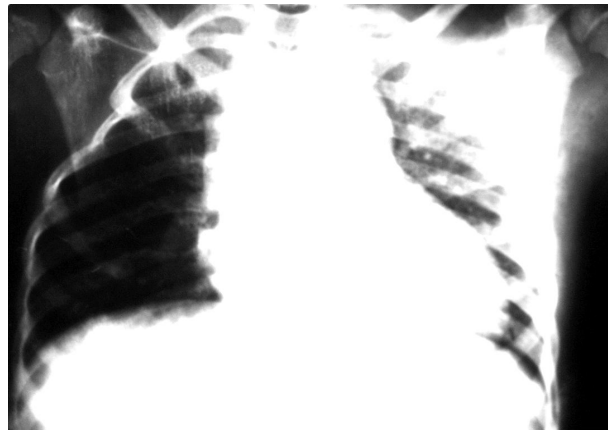


Fig. 2: Chest X-Ray of the same girl showing hyperlucent right-sided lung field due to absence of pectoralis major and minor muscles and hypoplastic third-rib on right side with small scapula on same side

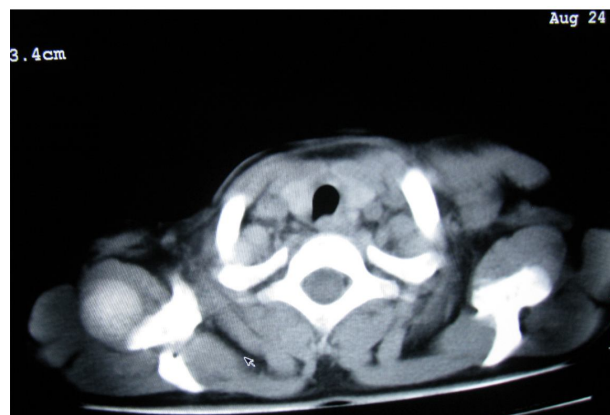


Fig. 3: CT thorax showing the absence of right-sided pectoralis major and minor muscles with hypoplastic scapula on right side

Author Affiliation: *Assistant Professor ****Associate Professor, Department of Paediatrics, VIMS, Bellary, Karnataka.

Reprint Request: Riyaz Ahmed F.K., Assistant Professor, Department of Paediatrics, Vijayanagara Institute of Medical Sciences (VIMS), Ballari, Karnataka 583104
E-mail: ramspsm@gmail.com

within normal limits. Chest radiograph showed hypoplastic 3rd rib with hyperlucent lung fields on right side due to absence chest muscles. Radiography of right hand confirmed the clinical findings. No other skeletal abnormalities were observed. USG abdomen and pelvis was normal.

Discussion

Poland syndrome is a unique pattern of unilateral malformations that are present at birth. First described by Sir Alfred Poland in 1841 is characterized by a defect of the chest (Pectoralis) muscle on one side of the body and webbing of the fingers (cutaneous syndactyly) of ipsilateral hand. The four essential features of this condition are:

1. Unilateral shortening of the index, long and ring fingers
2. Syndactyly of the affected digits
3. Hypoplasia of the hand (acromelia)
4. Absence of the sternocoastal portion of ipsilateral pectoralis muscle [1].

The incidence ranges from 1 in 7,000 to 1 in 1,00,000 live births [2]. The right side of body is affected three times more frequently than the left and it is three times more common in boys than girls [1]. The exact etiology of Poland's sequence is unknown, but may result from the interruption of fetal growth at about 46th day of pregnancy, when the fetal fingers and pectoralis muscle are developing [1]. Bouvet et al [3] and Bavnick et al [4] have suggested that the primary defect may

be in the development of the proximal subclavian artery with diminished blood flow to the affected side, leading to partial loss of tissue in that region.

Other associated anomalies with Poland's syndrome are scoliosis, moebius syndrome, renal hypoplasia and aplasia, spherocytosis, leukemia, lymphoma and pectus excavatum or carinatum. In left-sided Poland's syndrome, dextrocardia may be present [1].

In this patient most of external anomalies were present with normal systemic examination.

Chest X-Ray of the same girl showing hyperlucent right-sided lung field due to absence of pectoralis major and minor muscles and hypoplastic third-rib on right side with small scapula on same side CT thorax showing the absence of right-sided pectoralis major and minor muscles with hypoplastic scapula on right side.

References

1. <http://www.polands-syndrome.com/faq.htm>.
2. Fokin AA, Robicsek F. Polands syndrome revisited. *Ann Thorac Surg.* 2002; 74: 2218-5.
3. Bouvet J, Maroteaux P, Guillemot M. Poland's syndrome: Clinical and genetic studies. *Physiopathol Nouv-Press Med.* 1976; 5: 185.
4. Bavnick J, Weaver DD. Subclavian artery supply disruption sequence: hypothesis of a vascular etiology for Poland, Klippel-feil and Moebius anomalies. *Am J Med Genet.* 1986; 23: 903.